

Prevalence and severity of sacral dysmorphism and implications for safe transsacral screw placement in the Indigenous and non-Indigenous Australian population: A retrospective matched cohort study

James Virgin^{a,b,e,1,*} , Claudia Paul^{a,b,c} , Tim Cheok^{c,d,f} ,
Kanishka Williams^{a,c}, Mark Rickman^{b,e}, Lucian Bogdan Solomon^{b,e}, Boopalan Ramasamy^{b,e}

^a Department of Orthopaedic Surgery, Alice Springs Hospital, The Gap, Northern Territory

^b Department of Orthopaedic Surgery, The Royal Adelaide Hospital, Adelaide, South Australia, Australia

^c Department of Orthopaedic Surgery, Flinders Medical Centre, Bedford Park, South Australia, Australia

^d Department of Orthopaedic Surgery, The Prince Charles Hospital, Chermside, Queensland

^e Faculty of Health and Medical Sciences, The University of Adelaide, Adelaide, South Australia, Australia

^f College of Medicine and Public Health, Flinders University, Bedford Park, South Australia, Australia

ARTICLE INFO

Keywords:

Sacral dysmorphism
Indigenous
Transsacral fixation
Pelvic fracture
Sacral fracture

ABSTRACT

Objective: To compare prevalence and severity of sacral dysmorphism in Indigenous and non-Indigenous Australian populations.

Methods: We performed a single centre retrospective matched cohort study in consecutive Indigenous and non-Indigenous Australian patients who received a CT scan of the pelvis between January and March 2024 at our institution. Patients were excluded if they were under the age of 18 at the time of the scan or had a history of pelvic fractures or fixation. CT scans were assessed for both qualitative and quantitative features of sacral dysmorphism. The primary outcome of interest was the prevalence and severity of sacral dysmorphism in Indigenous and non-Indigenous Australian populations.

Results: 120 patients were included in the study - 60 Indigenous and 60 non-Indigenous Australians. All patients exhibited at least one characteristic of sacral dysmorphism. There was no difference in the prevalence of qualitative sacral dysmorphism between the two groups. Compared to their non-Indigenous counterpart, Indigenous patients demonstrated a lower S1 transsacral corridor coronal diameter (20.50 vs. 21.85 mm, $p = 0.005$), S1 oblique corridor axial diameter (17.90 vs. 19.60 mm, $p = 0.028$), S1 pelvic width (144.85 vs. 158.70 mm, $p < 0.001$), S2 transsacral corridor coronal diameter (13.70 vs. 14.95 mm, $p = 0.013$), S2 transsacral corridor axial diameter (10.60 vs. 11.55 mm, $p = 0.013$), and S2 pelvic width (126.60 vs 136.00 mm, $p < 0.001$). Additionally, in Indigenous patients, S1 and S2 transsacral and oblique S1 iliosacral fixation lengths were shorter. Where an S1 trans-sacral osseous corridor was not present, the S2 corridor was significantly larger in coronal, axial measurements across both groups ($p < 0.001$).

Conclusions: Indigenous Australian patients exhibited more severe forms of sacral dysmorphism when compared to their non-Indigenous counterparts. Additionally the overall prevalence of sacral dysmorphism across this Australian population was amongst the highest reported in the literature. This may present significant technical challenges and warrants consideration when performing percutaneous iliosacral screw fixation.

Introduction

The sacrum is essential in providing strength and stability to the pelvis, transmitting the body's entire weight to the pelvic girdle. It

protects neurovascular structures critical for bowel, urogenital, and lower limb neurological function [1,2]. Occurring in a cranial to caudal direction, fusion of the sacral vertebrae begins around puberty and typically completes in the third decade of life [3]. Sacral fractures

* Corresponding author.

E-mail address: james.virgin@adelaide.edu.au (J. Virgin).

¹ Present address: Department of Orthopaedic Surgery – Royal Adelaide Hospital, Port Road, Adelaide, South Australia.

represent a heterogeneous cohort, ranging from low-energy osteoporotic fractures to high-energy injuries. Specific mechanisms of injury are similarly diverse and can include any or all of compression, distraction or shearing forces. Although simple fractures can often be managed conservatively, complex unstable injuries may compromise the efferent lumbosacral nerve roots, necessitating surgical stabilisation [4]. Even simple fracture patterns resulting from low-energy trauma may lead to pain levels that restrict mobility requiring surgical management for early mobilisation [5].

Percutaneous iliosacral screw fixation is a well-established technique for managing unstable posterior pelvic injuries [6,7]. Anatomical variability of the upper sacral segments, also known as sacral dysmorphism, may complicate screw placement due to diminished safe osseous corridors [8,9]. Radiographical findings include (1) collinearity of the upper sacrum with the iliac crest within the pelvis (2); presence of mamillary bodies (3); irregularly shaped sacral foramen (4); residual disc between S1 and S2 (5); acute alar slope morphology, and (6) a “tongue-in-groove” appearance of the sacroiliac articulation (Fig. 1). Kaiser et al. have attempted to establish a sacral dysmorphism score correlating anatomical features with the presence of safe osseous pathways for screw placements [10]. Nevertheless, only one study has validated this score against the Singaporean population [11]. Inadvertent extra-osseous screw placement may result in iatrogenic injury to critical neurovascular structures [12]. Thus, understanding the morphological variation of the upper sacrum is essential to prevent this complication [13].

Previous research investigating ethnic differences in sacral dysmorphism revealed a higher prevalence in Japanese populations, also exhibiting a more restricted S1 safe osseous corridor compared to a Caucasian population [9]. The prevalence of sacral dysmorphism in the Australian population remains unknown. This study primarily aims to compare the prevalence and severity of sacral dysmorphism in both Indigenous and non-Indigenous Australian populations and its implications for safe transsacral screw passage. Additionally, we aim to validate the sacral dysmorphism score as outlined by Kaiser et al. [10], determine predictive factors affecting the lengths of the S1 and S2 safe transsacral osseous corridors, and analyse the characteristics of the S2 osseous corridor in pelvises that can accommodate an S1 transsacral screw compared with those that cannot.

Materials and methods

This is a retrospective matched cohort study reported in accordance with the Strengthening the Reporting of Observational Studies in Epidemiology (STROBE) guidelines [14]. Before commencing this study, approval was sought and obtained from the human research ethics committee (Approval No.: 2024–4972).

Patient selection

The radiology departments patient database at our institution was utilised to identify and recruit sixty consecutive Indigenous Australian patients who underwent computed tomography (CT) scans of the pelvis between January and March 2024. The indications for the scan were not standardised. Patients were excluded if (a) they were under the age of 18 at the time of the CT scan, (b) had evidence of pelvic or sacral fracture (acute or chronic), or (c) where scan quality was not appropriate for qualitative/quantitative assessment (as mutually agreed upon by the two independent reviewers). A separate cohort comprising 60 consecutive non-Indigenous Australian patients who received pelvic CT scans during this period and met the remaining inclusion and exclusion criteria were age- and sex-matched using the nearest neighbour technique. Indigenous and non-Indigenous self-reported ethnicity was identified utilising electronic medical records. Each scan was reviewed independently by two reviewers (JV and CP) and verified by senior authors (KW and BR). Both senior authors are fellowship-trained orthopaedic trauma surgeons with extensive experience in the management of sacral fractures.

Primary outcome

The primary outcome of interest was to compare the prevalence and severity of sacral dysmorphism between Indigenous and non-Indigenous Australian patients presenting to our institute. Six qualitative features of sacral dysmorphism were identified and recorded [15,16]. Features of interest include (1) collinearity of the upper sacrum with the iliac crest within the pelvis (2); presence of mamillary bodies (3); irregularly shaped sacral foramen (4); residual disc between S1 and S2 (5); acute alar slope morphology, and (6) a “tongue-in-groove” appearance of the sacroiliac articulation (Fig. 1). The severity of sacral dysmorphism was quantified using several indices: the S1 axial/coronal angle, the S1 axial/coronal corridor diameter, the S1 and S2 trans-sacral pelvic width, and the axial/coronal transsacral osseous corridor diameter.

Pelvic CT scans were reformatted such that the multiplanar reformatting (MPR) axis was perpendicular to the superior endplate of the second sacral segment (Fig. 2). The MPR axial and coronal slice was established as the point at which the S1 osseous corridor was widest. Respective axial and coronal osseous corridor angles and diameter were calculated on these slices. In keeping with previously described techniques; coronal angulation was measured as the angle formed between a line representing the coronal S1 osseous corridor and a line between the superior border of the iliac crests; and Axial angulation was measured as the angle formed between a line representing the axial S1 osseous corridor and a line between the posterior iliac spines (Fig. 3) [10]. The osseous corridor diameter was defined as the diameter of the canal perpendicular to the line of the axial and coronal angle at the level of the S1 foramina.

The transsacral corridor was defined as the diameter of the S1 and S2

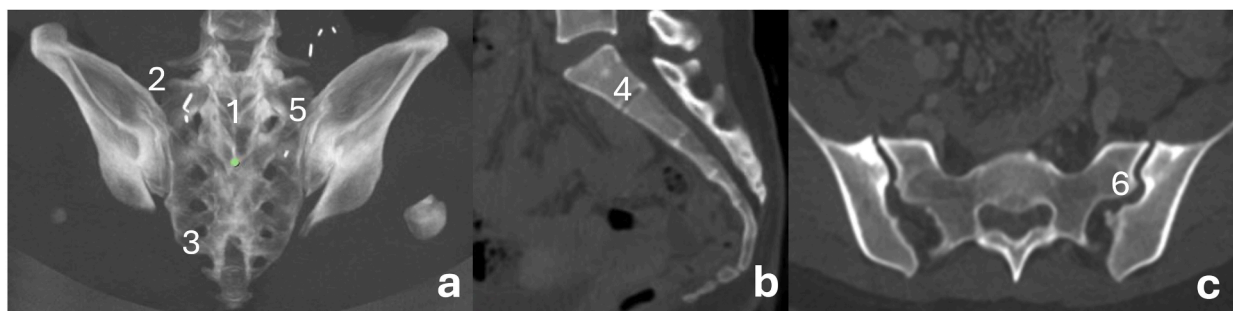


Fig. 1. Pelvic 3D reconstruction (a) and sagittal/axial CT slice (b/c) collectively demonstrating all six qualitative features of sacral dysmorphism; (1) collinearity of the upper sacrum with the iliac crest within the pelvis; (2) presence of mamillary bodies; (3) irregularly shaped sacral foramen; (4) residual disc between S1 and S2; (5) acute alar slope morphology, and (6) a “tongue-in-groove” appearance of the sacroiliac articulation.

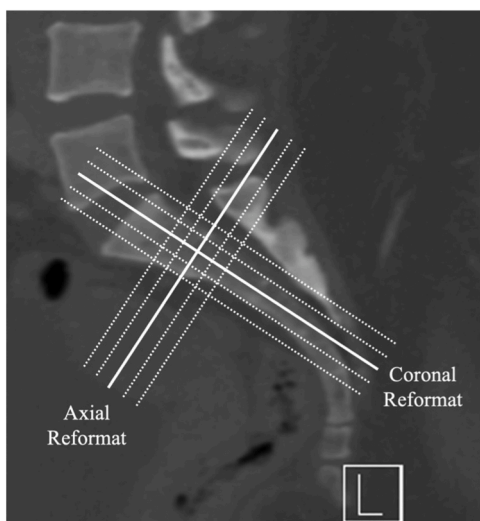


Fig. 2. Axial and coronal multiplanar reformatting (MPR) perpendicular to superior endplate of S2 sacral segment.

osseous corridors and was calculated on the original axial and coronal slices at their respective levels. Pelvic width was defined by the line which extends along the midpoint of the lines representing the anterior and posterior borders of the transsacral corridor at the S1 and S2 levels (Fig. 4). To satisfy the criteria for safe transsacral osseous corridor and screw passage, a corridor width of 10 mm was required in keeping with the previous literature [17]. In patients where a safe transsacral screw could not be passed due to the absence of a 10 mm corridor, oblique iliosacral osseous corridor diameter and length was calculated utilising a line of best fit (Fig. 5).

Secondary outcomes

The sacral dysmorphism score, as described by Kaiser et al., was calculated and recorded [10]. To assess model fit, we computed root mean square error (RMSE) values for the entire cohort of Indigenous and non-Indigenous patients. Smaller RMSE values indicate a better model fit [18]. We also evaluated whether the score threshold of 70 indicated the absence of a safe osseous corridor at the level of S1, as was proposed in their original study. Additionally, factors predicting the length of the S1 screw were established using a Least Absolute Shrinkage and Selection Operator (LASSO) technique for variable selection using age, sex, ethnicity, as well as all qualitative, and the remaining relevant quantitative measures as potential independent variables [19]. A transsacral

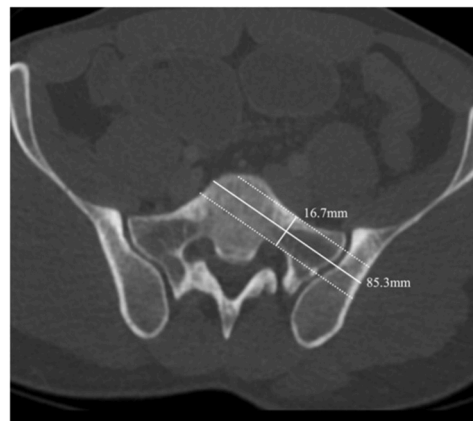


Fig. 5. S1 Axial slice utilised to calculate oblique iliosacral osseous corridor diameter and length.

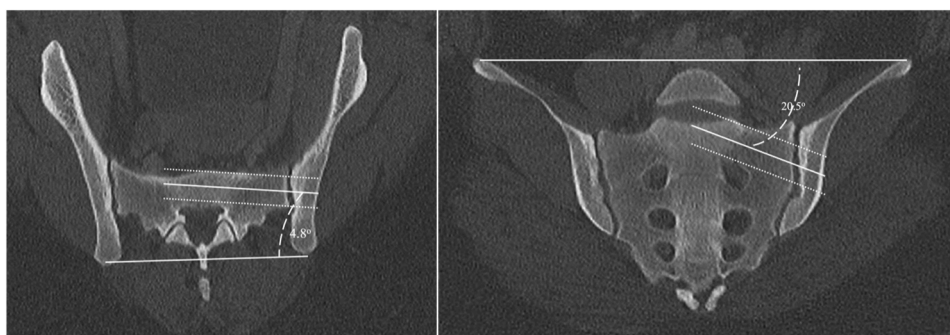


Fig. 3. MPR S1 axial and coronal slices utilised to calculate axial and coronal angulation and oblique corridor diameter.

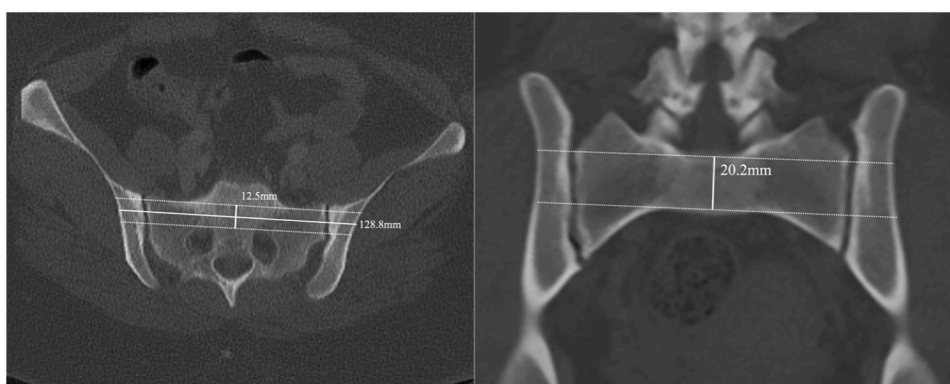


Fig. 4. S1 Axial and coronal slices utilised to calculate transsacral osseous corridor diameter and pelvic width.

corridor was favoured where possible, with the criteria as previously described. Where transsacral fixation was not possible, the length of the oblique iliosacral corridor was measured. Quantitative measures relevant for the S1 transsacral screw length included the S1 transsacral corridor coronal and axial diameters. In contrast, those appropriate for S1 oblique iliosacral screw length were S1 oblique corridor sagittal, coronal and axial diameters, as well as the S1 coronal and axial angulation. The sample was randomly divided into half to facilitate this analysis, forming training and validation datasets. The model's performance was established using the training dataset and subsequently compared to the expected values for the validation dataset using RMSE values.

Statistical analysis

The agreement was measured using Cohen's kappa for each qualitative feature, Pearson's correlation coefficient, and visual inspection of Bland-Altman's plots for quantitative measurements. Continuous outcomes were displayed as median (range) and compared using Wilcoxon's Rank Sum test, whereas binary outcomes were displayed as count (percentage) and compared using the chi-squared test. Statistical analysis was performed using Stata Version 18.0 (StataCorp LLC, Texas, USA). The threshold for statistical significance was set at $p < 0.05$.

Results

One hundred and twenty patients were included in the final analysis, with 60 patients in each group. Adequate age and sex matching was observed between the two groups, with no significant statistical differences in these parameters. In both groups, most CT scans were requested to investigate abdominal pain. Baseline demographics are displayed in [Table 1](#).

Primary outcome

There was no statistically significant difference in the prevalence of each qualitative feature of sacral dysmorphism ([Table 2](#)). All patients displayed at least one feature of sacral dysmorphism. Collinearity of the upper sacrum with the iliac crest within the pelvis was evident in nearly all patients from both the Indigenous and non-Indigenous groups (93.3 % vs 86.7 %, $p = 0.224$). Similarly, the presence of an irregularly shaped sacral foramen (56.7 % vs 61.7 %, $p = 0.577$), residual disc between S1 and S2 (53.3 % vs 53.3 %, $p = 1.000$), and the "tongue-in-groove" appearance of the sacroiliac articulation (53.3 % vs 50.0 %, $p = 0.715$) was noted in at least half of the patients in each group. Approximately a third of patients in both groups had mamillary bodies (38.3 % vs 36.7 %, $p = 0.850$) and acute alar slope morphology (30.0 % vs 38.3 %, $p = 0.336$). There was fair to moderate interobserver agreement between both reviewers.

Compared to non-Indigenous patients, Indigenous patients showed a

statistically significant reduction in S1 transsacral corridor coronal diameter (20.50 vs. 21.85, $p = 0.005$), S1 oblique corridor axial diameter (17.90 vs. 19.60, $p = 0.028$), S1 coronal angulation (11.00° vs. 16.00°, $p = 0.005$), and S1 pelvic width (144.85 mm vs. 158.70 mm, $p < 0.001$) ([Table 3](#)). A safe S1 transsacral osseous corridor for screw insertion was present in 44 Indigenous and 38 non-Indigenous patients (73.3 % vs. 63.3 % respectively). Where a safe S1 transsacral osseous corridor was present, the median length of the S1 transsacral corridor was shorter in Indigenous patients compared to their non-Indigenous counterparts (142.95 mm vs. 158.70 mm, $p < 0.001$). Among the remaining 16 Indigenous and 22 non-Indigenous patients where only an oblique iliosacral corridor was present, the median corridor length was shorter in Indigenous patients (85.50 mm vs. 92.70 mm, $p = 0.020$).

There was no significant difference in the S1 transsacral corridor axial diameter ($p = 0.346$), S1 oblique corridor sagittal diameter ($p = 0.482$), S1 oblique corridor coronal diameter ($p = 0.083$), and S1 axial angulation ($p = 0.794$) between the two groups. High to excellent interobserver agreement was observed among reviewers for all quantitative measurements, except for S1 axial diameter and S1 axial angulation, which exhibited moderate interobserver agreement.

Secondary outcomes

The sacral dysmorphism score demonstrated poor model performance in both our overall cohort (RMSE = 108.83) and among Indigenous (RMSE = 107.84) and non-Indigenous (RMSE = 109.78) patients in detecting safe screw passage. Sixteen patients had a sacral dysmorphism score greater than 70, all of whom lacked a safe S1 transsacral osseous corridor and therefore were deemed unsuitable for S1 transsacral screw fixation. Additionally, a safe S1 transsacral osseous corridor was absent in another 22 patients. As a result, the sensitivity and specificity of the predefined sacral dysmorphism score were 0.42 and 1.00, respectively. When divided into cohorts, the sensitivity was 0.31 in Indigenous patients and 0.50 in non-Indigenous patients.

The LASSO technique indicated that age, Indigenous status, and presence of mamillary bodies contributed to optimal model performance in predicting S1 transsacral corridor length. Among these variables, the S1 safe transsacral corridor length was significantly affected by both Indigenous status and the presence of mamillary bodies. Regression analysis determined that the S1 transsacral osseous corridor/pelvic width was 11.26 mm shorter in Indigenous patients, which was statistically significant ($p = 0.001$). Similarly, patients with mamillary bodies also displayed a reduced S1 pelvic width. The training model achieved an RMSE value of 9.61, whereas the validation dataset recorded an RMSE of 10.72. Our selected regression model output for S1 transsacral screw length is shown in [Table 4](#).

Age, Indigenous status, and the presence of collinearity between the upper sacrum and S1 coronal angulation contributed to optimal model performance in predicting the length of the S1 oblique iliosacral corridor, as determined using the LASSO technique. Among these selected variables, the length of the S1 safe oblique iliosacral screw was significantly influenced by age, Indigenous status, and S1 coronal angulation. For each year of increase in age, the screw length decreased by 0.15 mm ($p = 0.030$). Conversely, with every degree increase in S1 coronal angulation, the length of the S1 safe oblique iliosacral corridor increased by 0.78 mm ($p = 0.008$). Notably, Indigenous patients had a screw length that was 7.70 mm shorter compared to non-Indigenous patients ($p = 0.002$). The training model achieved an RMSE value of 4.11, while the validation dataset recorded an RMSE of 11.34. Our selected regression model output for S1 oblique iliosacral screw length is presented in [Table 5](#).

Safe S1 transsacral osseous corridor was not present in 38 patients – 16 Indigenous and 22 non-Indigenous patients ($p = 0.265$). In this group, seven patients (18.4 %) also did not possess a safe S2 transsacral osseous corridor – four of whom were Indigenous. In the absence of a safe S1 corridor, the absence of both S1 and S2 corridor was greater in

Table 1
Demographic data of Indigenous vs non-Indigenous Australian patients.

	Indigenous (n = 60)	Non- Indigenous (n = 60)	p-Value
Age, yrs	45.00 (20.00 – 75.00)	52.50 (20.00 – 94.00)	0.105
Sex, n (%)			1.000
Male	30 (50.0)	30 (50.0)	
Female	30 (50.0)	30 (50.0)	
Indication, n (%)			0.379
Abdominal Pain	50 (83.3)	54 (90.0)	
Malignancy Surveillance	2 (3.3)	1 (1.7)	
Trauma Series	5 (8.3)	1 (1.7)	
Septic Screen	1 (1.7)	1 (1.7)	
Unknown	2 (3.3)	3 (5.0)	

Table 2
Morphological features of sacral dysmorphism.

Morphological Feature	Group		p-Value	Agreement	
	Indigenous (n = 60)	Non- Indigenous (n = 60)		Interobserver (%)	Kappa Statistic
Collinearity of the Upper Sacrum	56 (93.3)	52 (86.7)	0.224	90.0	0.40 (Fair)
Mamillary Bodies	23 (38.3)	22 (36.7)	0.850	76.7	0.52 (Moderate)
Irregularly Shaped Sacral Foramen	34 (56.7)	37 (61.7)	0.577	68.3	0.35 (Fair)
Residual Disc between S1 and S2	32 (53.3)	32 (53.3)	1.000	73.3	0.47 (Moderate)
Acute Alar Slope Morphology	18 (30.0)	23 (38.3)	0.336	74.2	0.37 (Fair)
Tongue in Groove Appearance of the Sacroiliac Articulation	32 (53.3)	30 (50.0)	0.715	70.8	0.42 (Moderate)

Table 3
Quantitative measurements of safe osseous corridor.

Measurement	Group		p-Value	Pearson Correlation
	Indigenous Australian (n = 60)	Non-Indigenous Australian (n = 60)		
S1 Oblique Corridor Sagittal Diameter, mm	21.20 (17.00 – 27.10)	21.55 (14.00 – 27.40)	0.482	0.55 (Moderate)
S1 Oblique Corridor Coronal Diameter, mm	18.50 (12.40 – 27.60)	19.15 (12.60 – 24.00)	0.083	0.73 (High)
S1 Oblique Corridor Axial Diameter, mm	17.90 (11.80 – 29.00)	19.60 (12.80 – 25.80)	0.028	0.51 (Moderate)
S1 Coronal Angulation, °	11.00 (0 – 31.00)	16.00 (1.00 – 31.00)	0.005	0.69 (High)
S1 Axial Angulation, °	7.00 (1.00 – 32.00)	7.00 (0 – 31.00)	0.794	0.50 (Moderate)
S1 Transsacral Corridor Coronal Diameter, mm	20.50 (12.40 – 25.20)	21.85 (10.70 – 28.00)	0.005	0.65 (High)
S1 Transsacral Corridor Axial Diameter, mm	12.20 (0 – 22.90)	11.55 (0 – 23.40)	0.346	0.93 (Excellent)
S1 Pelvic Width, mm	144.85 (125.10 – 166.00)	158.70 (133.10 – 191.00)	<0.001	0.88 (Excellent)
S1 Safe Transsacral Screw Length, mm*	142.95 (125.10 – 166.00)	158.20 (133.10 – 175.00)	<0.001	0.87 (Excellent)
S1 Safe Iliosacral Screw Length, mm*	85.50 (70.00 – 99.20)	92.70 (79.00 – 107.00)	0.020	0.63 (High)
S2 Transsacral Corridor Coronal Diameter, mm	13.70 (8.70 – 20.70)	14.95 (7.50 – 22.80)	0.013	0.75 (High)
S2 Transsacral Corridor Axial Diameter, mm	10.60 (6.70 – 15.40)	11.55 (6.00 – 17.90)	0.036	0.70 (High)
S2 Pelvic Width	128.60 (106 – 153.50)	136.00 (97.00 – 183.00)	<0.001	0.65 (High)

Table 4
Determinants of S1 transsacral screw length following LASSO variable selection. Root mean square error = 9.61 (Training); 10.72 (Validation).

Variable	Coefficient	Standard Error	p-Value
Age, years	0.16	0.11	0.151
Australian Indigenous	-11.26	3.21	0.001
Presence of Mamillary Bodies	-7.38	3.23	0.028
Constant	150.49	7.01	

Table 5
Determinants of S1 oblique iliosacral screw length if transsacral screw is not possible following LASSO variable selection. Root mean square error = 4.11 (Training); 11.34 (Validation).

Variable	Coefficient	Standard Error	p-Value
Age, years	-0.15	0.06	0.030
Australian Indigenous	-7.70	2.04	0.002
Presence of Collinearity of the Upper Sacrum	-3.32	2.51	0.207
S1 Coronal Angulation, °	0.78	0.25	0.008
Constant	84.48	7.01	

the Indigenous population (25 % vs 13.6 %). Compared to those in which an S1 safe transsacral osseous corridor was present, those who did not have a safe S1 transsacral osseous corridor exhibited a significantly larger S2 coronal diameter (16.40 mm vs 13.75 mm, $p < 0.001$), S2 axial diameter (13.70 mm vs 10.60 mm, $p < 0.001$), and S2 transsacral pelvic width (138.00 mm vs 130.35 mm, $p < 0.001$). Our analysis is displayed in [Table 6](#).

Discussion

The results of this study found no difference in the prevalence of qualitative features of sacral dysmorphism between Indigenous and non-Indigenous Australian patients. All patients included in the study possessed at least one qualitative feature, with one-third displaying three out of the six characteristics. Although the prevalence of sacral dysmorphism in Indigenous patients was not significantly different from that of their non-Indigenous counterparts, nearly all quantitative measurements indicated that Indigenous patients exhibited more severe forms of dysmorphism. Indigenous patients showed a smaller S1 transsacral corridor diameter, S1 oblique corridor axial diameter, S1 pelvic width, and S2 transsacral coronal and axial diameters.

The prevalence of sacral dysmorphism varies considerably in the literature [10,20–22], with one study reporting rates as high as 85 % [21]. Variation in the prevalence of sacral dysmorphism is not novel; several studies have suggested that East Asian and South Asian Indian patients have a higher rate compared to their European counterparts [9, 23,24]. Notably one study demonstrated that 23 % of European patients and 30 % of Japanese patients exhibited clinically significant

Table 6
Characteristics of the S2 osseous corridor in patients where an S1 transsacral screw is not possible.

Measurement	Possibility of an S1 Transsacral Screw		p-Value
	Not Possible (n = 31)	Possible (n = 82)	
S2 Coronal Diameter, mm	16.40 (10.10 – 22.80)	13.75 (7.50 – 20.70)	< 0.001
S2 Axial Diameter, mm	13.70 (10.10 – 17.90)	10.60 (6.00 – 15.40)	< 0.001
S2 Safe Screw Length, mm	138.00 (119.50 – 183.00)	130.35 (97.00 – 164.00)	< 0.001

dysmorphism as described by having a S1 corridor <8 mm in either axial or coronal diameter [9]. Despite the utilisation of the more widely accepted 10 mm S1 safe corridor, the rates of clinically significant sacral dysmorphism in our study are relatively comparable to those reported by Wagner et al. (i.e. 26.6 % and 36.6 % in the Indigenous and non-Indigenous populations, respectively). Previous studies have hypothesised that differences in the prevalence of sacral dysmorphism may partly result from variations in early upright locomotion, with higher rates of dysmorphism observed in paraplegic children [25].

A dysmorphic upper sacral segment presents significant technical challenges for iliosacral screw placement. The increased obliquity of this segment necessitates a more posterior and caudal starting point [26]. In these patients, oblique S1 or S2/S3 iliosacral/transsacral fixation should be considered [27,28]. Additionally, guidewire placement using intra-operative CT or navigation systems could also be considered [29,30]. When considering previous literature and the sacral dysmorphism score proposed by Kaiser et al. [10] utilising a cut-off of 70 had perfect specificity but poor sensitivity in our cohort, which was worse in Indigenous patients. Although a score above 70 accurately predicted the inability to insert an S1 transsacral screw, clinicians need to be mindful that in a significant proportion of patients with a score of <70, the insertion of an S1 transsacral screw was still not possible with absence of a safe osseous corridor.

In our study, the lengths of S1 and S2 safe transsacral corridors were shorter in Indigenous patients, even after adjusting for covariates. Research indicates that shorter screw lengths are biomechanically inferior, potentially leading to early construct failure [31–33]. We also demonstrated that when S1 transsacral fixation is not possible, S2 transsacral fixation appears to be more favourable. Several previous studies have indicated that in patients with sacral dysmorphism, S2 transsacral screws tend to be a safer option, consistent with our findings [15,20,34]. However, there is currently limited literature on the safety and efficacy of S2 transsacral screw fixation, indicating a need for further research [8,35,36].

This study is the first to quantify the prevalence and severity of sacral dysmorphism in Indigenous and non-Indigenous Australian populations. However, several limitations need to be addressed. Firstly, we could only determine the sample size after the commencement of this study due to a lack of published data in the literature. A post hoc sample size calculation indicated that although this study is not powered to conclude the qualitative measurement of sacral dysmorphism, most quantitative outcomes were sufficiently powered. Importantly, all three regression analyses had a power greater than 95 %. Furthermore, although each quantitative and qualitative measure was assessed by two authors and verified by the senior authors, there was only fair to moderate interobserver agreement regarding the quantitative measures. These agreement statistics are similar to those reported in previous literature(10). Notably there was significantly better agreement in qualitative measures. Finally, the non-Indigenous group was heterogeneous, as more specific ethnicity information could not be acquired.

Conclusion

Despite similar prevalence, this study suggests that Indigenous Australians exhibit more severe forms of sacral dysmorphism compared to their non-Indigenous counterparts. Additionally the overall prevalence of sacral dysmorphism across this Australian population was amongst the highest reported in the literature. The sacral dysmorphism score was highly specific but not sensitive in predicting the absence of a safe S1 transsacral osseous corridor and, thus, the safe insertion of S1 transsacral screws. When managing Indigenous Australian patients with transsacral screw fixation, surgeons should be mindful of the shorter and narrower safe osseous corridors. Even when adjusted for confounding factors, the lengths of S1 transsacral, S1 oblique iliosacral, and S2 transsacral fixation were all shorter in Indigenous patients. The findings of this paper support S1 oblique iliosacral and S2 transsacral fixation

configurations in patients with clinically significant sacral dysmorphism due to the relatively favourable anatomy; Additionally consideration should be given to the emerging role of novel patient-specific curved iliosacral implants in surgically complex cases [37].

Ethics in publishing statement

I testify on behalf of all co-authors that our article submitted followed ethical principles in publishing.

This research presents an accurate account of the work performed, all data presented are accurate and methodologies detailed enough to permit others to replicate the work.

This manuscript represents entirely original works and or if work and/or words of others have been used, that this has been appropriately cited or quoted and permission has been obtained where necessary.

This material has not been published in whole or in part elsewhere.

The manuscript is not currently being considered for publication in another journal.

That generative AI and AI-assisted technologies have not been utilized in the writing process or if used, disclosed in the manuscript the use of AI and AI-assisted technologies and a statement will appear in the published work.

That generative AI and AI-assisted technologies have not been used to create or alter images unless specifically used as part of the research design where such use must be described in a reproducible manner in the methods section.

All authors have been personally and actively involved in substantive work leading to the manuscript and will hold themselves jointly and individually responsible for its content.

CRediT authorship contribution statement

James Virgin: Writing – review & editing, Resources, Project administration, Methodology, Formal analysis, Data curation, Conceptualization. **Claudia Paul:** Writing – review & editing, Resources, Methodology, Investigation, Formal analysis, Conceptualization. **Tim Check:** Writing – review & editing, Writing – original draft, Methodology, Formal analysis. **Kanishka Williams:** Writing – review & editing, Supervision, Methodology, Conceptualization. **Mark Rickman:** Writing – review & editing, Supervision, Methodology, Conceptualization. **Lucian Bogdan Solomon:** Writing – review & editing, Supervision, Methodology, Conceptualization. **Boopalan Ramasamy:** Writing – review & editing, Supervision, Methodology, Conceptualization.

Declaration of competing interest

Nil.

Acknowledgments

None.

References

- [1] Dalley AF, Agur AMR. Moore's clinically oriented anatomy. 9th ed. Philadelphia: Wolters Kluwer; 2023.
- [2] Bydon M, De la Garza-Ramos R, Macki M, Desai A, Gokaslan AK, Bydon A. Incidence of sacral fractures and in-hospital postoperative complications in the United States: an analysis of 2002-2011 data. *Spine* 2014;39(18):E1103–9 (Phila Pa 1976).
- [3] Gray H. Anatomy of the human body. *Am J Med Sci* 1919;157(5):704.
- [4] Santolini E, Kanakaris NK, Giannoudis PV. Sacral fractures: issues, challenges, solutions. *EFORT Open Rev* 2020;5(5):299–311.
- [5] Wilson DGG, Kelly J, Rickman M. Operative management of fragility fractures of the pelvis - a systematic review. *BMC Musculoskelet Disord* 2021;22(1):717.
- [6] Osterhoff G, Ossendorf C, Wanner GA, Simmen H-P, Werner CML. Percutaneous iliosacral screw fixation in S1 and S2 for posterior pelvic ring injuries: technique and perioperative complications. *Arch Orthop Trauma Surg* 2011;131(6):809–13.

- [7] Routt Jr ML, Gregor PJ, Simonian PT, Mayo KA. Early results of percutaneous iliosacral screws placed with the patient in the supine position. *J Orthop Trauma* 1995;9(3):207–14.
- [8] Zheng J, Xiang J, Feng X, Liu F, Chen K, Chen B. Applicable safety analysis and biomechanical study of iliosacral triangular osteosynthesis. *BMC Musculoskelet Disord* 2021;22(1):971.
- [9] Wagner D, Kamer L, Sawaguchi T, Geoff Richards R, Noser H, Uesugi M, et al. Critical dimensions of trans-sacral corridors assessed by 3D CT models: relevance for implant positioning in fractures of the sacrum. *J Orthopaedic Res* 2017;35(11):2577–84.
- [10] Kaiser SP, Gardner MJ, Liu J, Routt Jr ML, Morshed S. Anatomic determinants of sacral dysmorphism and implications for safe Iliosacral screw placement. *J Bone Joint Surg Am* 2014;96(14):e120.
- [11] Teo AQA, Yik JH, Jin Keat SN, Murphy DP, O'Neill GK. Accuracy of sacroiliac screw placement with and without intraoperative navigation and clinical application of the sacral dysmorphism score. *Injury* 2018;49(7):1302–6.
- [12] Esses SI, Botsford DJ, Huler RJ, Rauschnig W. Surgical anatomy of the sacrum. A guide for rational screw fixation. *Spine* 1991;16:S283–8. *Phila Pa* 19766 Suppl.
- [13] Farrell ED, Gardner MJ, Krieg JC, Routt Jr MLC. The upper sacral nerve root tunnel: An anatomic and clinical study. *J Orthop Trauma* 2009;23(5):333–9.
- [14] von Elm E, Altman DG, Egger M, Pocock SJ, Gøtzsche PC, Vandenbroucke JP. The strengthening the reporting of observational studies in epidemiology (STROBE) statement: guidelines for reporting observational studies. *J Clin Epidemiol* 2008;61(4):344–9.
- [15] Conflitti JM, Graves ML, Chip Routt Jr ML. Radiographic quantification and analysis of dysmorphic upper sacral osseous anatomy and associated iliosacral screw insertions. *J Orthop Trauma* 2010;24(10):630–6.
- [16] Routt Jr ML, Simonian PT, Agnew SG, Mann FA. Radiographic recognition of the sacral alar slope for optimal placement of iliosacral screws: a cadaveric and clinical study. *J Orthop Trauma* 1996;10(3):171–7.
- [17] Woods D, Koerner J, Strage K, Chu X, Simon V, Hadeed M, et al. Defining sacral dysmorphism: what size corridor precludes transsacral screw placement. *J Orthop Trauma* 2022;36(10):498–502.
- [18] Schubert A-L, Hagemann D, Voss A, Bergmann K. Evaluating the model fit of diffusion models with the root mean square error of approximation. *J Math Psychol* 2017;77:29–45.
- [19] Ranstam J, Cook JA. LASSO regression. *Br J Surg* 2018;105(10):1348.
- [20] Hasenboehler EA, Stahel PF, Williams A, Smith WR, Newman JT, Symonds DL, et al. Prevalence of sacral dysmorphism in a prospective trauma population: implications for a "safe" surgical corridor for sacro-iliac screw placement. *Patient Saf Surg* 2011;5(1):8.
- [21] Weigelt L, Laux CJ, Slankamenac K, Ngyuen TDL, Osterhoff G, Werner CML. Sacral dysmorphism and its implication on the size of the sacroiliac joint surface. *Clin Spine Surg* 2019;32(3):E140. e4.
- [22] Alshaalan FN, Al-Mohrej OA, Hakeem NN, Al-Asiri J, Johal H. Sacral dysmorphism and its influence on hardware choice in sacral fractures: A scoping review. *J Orthop Trauma Rehabil* 2024;32(1):94–106. <https://doi.org/10.1177/22104917241256657>.
- [23] Wu C, Liu YC, Koga H, Lee CY, Wang PY, Cher D, et al. Ethnic differences in Western and Asian sacroiliac joint anatomy for surgical planning of minimally invasive sacroiliac joint fusion. *Diagnostics* 2023;13(5):883.
- [24] Trikha V, Gaba S, Kumar A, Mittal S, Kumar A. Safe corridor for iliosacral and trans-sacral screw placement in Indian population: a preliminary CT based anatomical study. *J Clin Orthop Trauma* 2019;10(2):427–31.
- [25] Miller AN, Routt Jr ML. Variations in sacral morphology and implications for iliosacral screw fixation. *J Am Acad Orthop Surg* 2012;20(1):8–16.
- [26] Wendt H, Gottschling H, Schröder M, Marintschev I, Hofmann GO, Burgkart R, et al. Recommendations for iliosacral screw placement in dysmorphic sacrum based on modified in-out-in corridors. *J Orthopaedic Res* 2019;37(3):689–96.
- [27] Eastman JG, Adams MR, Frisoli K, Chip Routt Jr ML. Is S3 a viable osseous fixation pathway? *J Orthop Trauma* 2018;32(2):93–9.
- [28] Hwang JS, Reilly MC, Shaath MK, Changoor S, Eastman J, Routt ML, et al. Safe zone quantification of the third sacral segment in normal and dysmorphic sacra. *J Orthop Trauma* 2018;32(4):178–82.
- [29] Khan JM, Lara DL, Marquez-Lara A, Rosas S, Hasty E, Pilon HT. Intraoperative CT and surgical navigation for iliosacral screws: technique for patients with sacral dysmorphism. *J Orthop Trauma* 2018;32:S24–5.
- [30] Matiyahu A, Kahler D, Krettek C, Stöckle U, Grutzner PA, Messmer P, et al. Three-dimensional navigation is more accurate than two-dimensional navigation or conventional fluoroscopy for percutaneous sacroiliac screw fixation in the dysmorphic sacrum: a randomized multicenter study. *J Orthop Trauma* 2014;28(12):707–10.
- [31] Ma Y, Zhao Y, Zou D, Dong S, Sun X, Cheng G, et al. Breakage risk of different sacroiliac screws in unilateral sacral fractures a finite element analysis. *BMC Musculoskelet Disord* 2022;23(1):953.
- [32] Gardner MJ, Routt Jr MLC. Transiliac–transsacral screws for posterior pelvic stabilization. *J Orthop Trauma* 2011;25(6):378–84.
- [33] Wu Q, Zhang Y, Wang S, Liu R, Liu G. Different lengths of percutaneous transverse iliosacral screw in geometric osseous fixation pathway: a finite-element analysis. *Indian J Orthop* 2022;56(8):1354–62.
- [34] Mendel T, Noser H, Kuervers J, Goehre F, Hofmann GO, Radetzki F. The influence of sacral morphology on the existence of secure S1 and S2 transverse bone corridors for iliosacroiliac screw fixation. *Injury* 2013;44(12):1773–9.
- [35] Moed BR, Geer BL. S2 iliosacral screw fixation for disruptions of the posterior pelvic ring: a report of 49 cases. *J Orthop Trauma* 2006;20(6):378–83.
- [36] Carlson DA, Scheid DK, Maar DC, Baele JR, Kaehr DM. Safe placement of S1 and S2 iliosacral screws: the "vestibule" concept. *J Orthop Trauma* 2000;14(4):264–9.
- [37] Zakariaee R, Schlosser CL, Baker DR, Meek RN, Coope RJN. A feasibility study of pelvic morphology for curved implants. *Injury* 2016;47(10):2195–202.